



HAL
open science

Nodal metastases distribution in laryngeal cancer requiring total laryngectomy: Therapeutic implications for the N0 Neck

D. Rivière, J. Mancini, L. Santini, A. Loth Bouketala, A. Giovanni, P. Dessi, N. Fakhry

► To cite this version:

D. Rivière, J. Mancini, L. Santini, A. Loth Bouketala, A. Giovanni, et al.. Nodal metastases distribution in laryngeal cancer requiring total laryngectomy: Therapeutic implications for the N0 Neck. *European Annals of Otorhinolaryngology, Head and Neck Diseases*, 2019, 136 (3), pp.S35-S38. 10.1016/j.anorl.2018.08.011 . hal-02613535

HAL Id: hal-02613535

<https://hal-amu.archives-ouvertes.fr/hal-02613535>

Submitted on 22 Oct 2021

HAL is a multi-disciplinary open access archive for the deposit and dissemination of scientific research documents, whether they are published or not. The documents may come from teaching and research institutions in France or abroad, or from public or private research centers.

L'archive ouverte pluridisciplinaire **HAL**, est destinée au dépôt et à la diffusion de documents scientifiques de niveau recherche, publiés ou non, émanant des établissements d'enseignement et de recherche français ou étrangers, des laboratoires publics ou privés.



Distributed under a Creative Commons Attribution - NonCommercial | 4.0 International License

**TITLE: Nodal metastases distribution in laryngeal cancer requiring total laryngectomy:
therapeutic implications for the N0 Neck**

Names of authors : Damien RIVIERE, MD (1,2) ; Julien MANCINI, MD (3, 4,5) ; Laure SANTINI, MD (1) ; Anthony LOTH BOUKETALA (1) ; Antoine GIOVANNI, PhD (1) ; Patrick DESSI, PhD (1) ; Nicolas FAKHRY, PhD (1).

(1) Service d'ORL et de Chirurgie Cervico-Faciale, Centre Hospitalier Universitaire La Conception, Aix Marseille Univ, 147 Boulevard Baille, 13005, Marseille, France.

(2) Ecole du Val-de-Grâce, Paris, France.

(3) Aix Marseille Université, UMR912, IRD, SESSTIM, Marseille, France.

(4) INSERM, UMR912 (SESSTIM), Marseille, France.

(5) APHM, Hôpital de la Timone, BiosTIC, Marseille, France.

Presented at the 48th Annual Meeting of the SFCCF: Société Française de Carcinologie Cervico-Faciale (French Society of Head and Neck Cancer), Toulouse, France, November 20–21, 2015.

A poster of this work was presented at the 5th ENT World Congress, IFOS 2017, Paris.

Corresponding Author:

Nicolas Fakhry, PhD (E-mail: nicolas.fakhry@ap-hm.fr)

Assistance Publique - Hôpitaux de Marseille (AP-HM) / Aix – Marseille Univ – Centre Hospitalier Universitaire (CHU) la Conception - Service ORL and Chirurgie Cervico-Faciale
147 Boulevard Baille, 13005 MARSEILLE, France

Phone number: 00. 33. 4. 91. 43. 55. 20. Fax: 00. 33. 4. 91. 43. 57. 99.

Abstract

OBJECTIVES

Neck dissection is a controversial surgical procedure in patients with squamous cell carcinoma of the Larynx free of any node metastasis detected in preoperative staging. The aim of this study was to investigate the distributions of lymph node metastases in laryngeal squamous cell carcinoma and improve the rationale for elective treatment of N0 neck.

MATERIAL AND METHODS

Retrospective single-center series of Seventy eight successive patients with laryngeal squamous cell carcinoma who underwent neck dissection between 2008 and 2015.

RESULTS

Surgery was first-line treatment in 37 patients (47%) and for recurrent disease in 41 (53%). The rate of occult nodal metastasis was 14% (N=11): levels IIa and/or III were affected in 9 cases (11.5%) compared with single cases of IIb and IV involvement (1.3% each). The rate of occult nodal metastasis was significantly lower among patients operated on for recurrent disease after radiotherapy than in patients who never had any radiotherapy of the cervical lymph nodes (0% vs 16.7%, p=0.03).

CONCLUSIONS

Selective cervical lymph node dissection in levels IIa and III sparing levels IIb and IV seems to be ideal in total laryngectomy in patients with cN0 laryngeal squamous cell carcinoma. Omitting lymph node dissection altogether may be considered in total laryngectomy on a cN0 patient showing recurrence after radiotherapy.

Key Words : Laryngeal squamous cell carcinoma; elective neck dissection; N0 neck; salvage laryngectomy; primary laryngectomy.

Introduction

The presence of a cervical node metastasis is one of the most significant prognostic factors in treating patients for laryngeal squamous cell carcinoma (SCC) [1]. Lymph node treatment is usually required in all cases of SCC of the Larynx with the exception of glottis cancer. Lymph nodes metastasis is one of the most serious prognostic signs in patients with SCC of the larynx [2].

In all clinically N-positive neck patients undergoing total laryngectomy (TL), the presence of histologically confirmed metastasis is associated with a high risk of recurrence and a decrease in the survival rate of up to 50 % [3]. However, the complete cervical dissection remains controversial in management of the preoperative cN0 neck. Indeed, this surgery can cause significant morbidity, including accessory or phrenic nerve damages, injury of the thoracic duct and vessels injuries, especially after a post-radiotherapy surgery [4, 5]. To decrease that postoperative morbidity, some experts have recently proposed a highly selective neck dissection (levels IIa and III specifically). Indeed, the omission of level IIb neck dissection is widely studied and seem justified because this level is less sensitive to lymph node metastases. The rate of lymph node metastases in level IV is less studied but its omitting is also described [6, 7, 8]. The aim of this study was to investigate the distributions of lymph node metastases in laryngeal squamous cell carcinoma (SCC), to identify some predictive factors for occult node metastasis in clinically N-negative neck and to improve the rationale for elective treatment of N0 neck.

Materials and methods

Between January 2008 and September 2015, 178 patients with laryngeal cancer were admitted to and treated at the department of otorhinolaryngology at la Conception Hospital, Marseilles, France. All these patients had a total laryngectomy. The following criteria were required for inclusion in this study: 1) patients with histologically confirmed SCC, 2) patients without an associated ENT cancer or a distant metastasis at the time of initial presentation, 3) a complete medical record. Seventy eight patients met these criteria and were included in the study.

The patient charts were examined, retrospectively, for sex, TNM status, number and level of cervical node metastases. Tumor were staged using physical examination, endoscopy and computed tomography (neck and chest), according to the guidelines in the American Joint Committee Staging System (Sixth Edition). All patients were N-negative neck after the preoperative findings and a neck dissection was performed in all of them. All the medical records were discussed in a multidisciplinary head and neck cancer meeting. A selective neck dissection (involving lymph nodes IIa, IIb, III and IV), ipsi or/and bilateral, was performed in all patients, according to a routine practice in our Department.

For tumors of the larynx above and below the glottis or going beyond the median line, neck dissection had been bilateral. Central compartment neck dissection was not carried out in any patient in this population, this procedure being reserved for N+ cases. Surgical lymph nodes specimens were divided in different levels and then sent to the pathology department for a permanent section analysis. Histopathologic examination of the metastases included the number and location of the nodes containing metastatic disease. The relationship between the cervical lymphatic metastasis distribution and clinicopathologic factors was assessed by a χ^2 test or Fisher exact test. Statistical significance was defined as $p \leq 0.05$. Statistical tests were

carried out using the IBM SPSS Statistics 20.0 package (IBM Inc., New York, USA). This work was approved by the Institutional Review Board of la Conception Hospital.

Results

The patient population, which included 72 men and 6 women, had a mean age of 64 years (range: 38-83). The characteristics of the population is given in Table 1 (sex, TNM, primary site distribution, primary or salvage total laryngectomy). Thirty patients were cT3N0 (39%), 44 were cT4N0 (56%) and 4 were cT2N0 (5%). All T2N0 patients were operated on in a salvage context, in which conservative surgery was excluded. The primary site distribution was the following: glottic in 25 patients (32%), subglottic in 3 patients (4%), supraglottic in 7 patients (9%) and transglottic in 43 patients (55%). TL was the first-line treatment in 37 patients (47%). On the contrary, 41 patients (53%) were operated on for a recurrent cancer. Among them, 12 patients had already had radiotherapy on neck lymph nodes. Neck dissection was performed before resection of the primary tumor. It was ipsilateral in 23 cases (29.5%) and bilateral in 55 (70.5%). The median follow-up was 28 months (range: 0-85).

An average of 21 (range: 9-72) lymph nodes was collected from each neck. Of the 133 specimens evaluated, 11 patients had occult nodal metastasis (14%) including one case (1.3%) with an extracapsular spread in level III. Level II and III were the most frequently affected, with a prevalence of 11.5 % (9 patients). The incidences of cervical metastasis at level IIb and IV was respectively 1.3 % (1 patient) and 1.3 % (1 patient) (Figure 1). Among the 11 patients showing node invasion, the tumor was glotto-subglottic in 2 cases (18.2%), subglottic in 1 case (9.1%), supraglottic in 2 cases (18.2%) and transglottic in 6 cases (54.5%). One patient had developed a metastasis in a single contralateral lymph node in level IIa. It was about a tumour classified cT4aN0.

All patients who showed occult nodal metastasis in histological analysis had locally advanced T3 or T4 tumors. Three patients had a tumor recurrence: two after exclusive conservative surgery (laser cordectomy) and one after induction chemotherapy failure. There was no statistically significant difference between the frequency of occult nodal metastasis and tumor stage ($p=0.53$), tumor sublocalization ($p=0.66$) and a previous surgical treatment (laser cordectomy or partial laryngectomy) for a recurrent laryngeal cancer ($p=0.57$) (Table 2). In contrast, the rate of occult nodal metastasis was significantly lower after a recurrent laryngeal cancer treated by radiotherapy compared to patients with a recurrence free of any previous radiotherapy (0% vs 16.7%, $p=0.03$).

Discussion

The type of neck dissection remains controversial in N-negative neck patients treated by total laryngectomy. Currently, the preferred option is a functional neck dissection in levels II through IV. Indeed, metastasis at levels I and V being considered as very rare. A selective neck dissection (II-III-IV levels) became popular in 2002 based on the revision of the guidelines of the American Academy of Otolaryngology-Head and Neck Surgery, subsequently reinforced by the National Comprehensive Cancer Network [9, 10]. It is now accepted that nodes on both sides ought to be dissected with supra or subglottic tumors or extending beyond the median line since these regions are characterised by bilateral lymphatic drainage [10]. This procedure is nevertheless associated with significant morbidity, including accessory or phrenic nerve damages, injury of the thoracic duct and vessels injuries, especially after a post-radiotherapy surgery. The meta-analysis of Paydarfar et al. showed that the combination of cervical lymph node dissection and preoperative radiotherapy is a risk factor for pharyngocutaneous fistula [5].

Recently, some studies showed that a selective neck dissection of sublevel IIA and level III appears to be adequate for elective surgical treatment of the neck in supraglottic and glottic squamous carcinoma. Dissection of level IV lymph nodes may not be justified for elective neck dissection of stage N0 supraglottic and glottic squamous carcinoma. Bilateral neck dissection in cases of supraglottic cancer may be necessary only in patients with centrally or bilaterally located tumors [11]. For more advanced tumors, functional neck dissection in levels II through IV remains standard since the rate of occult metastasis cannot be ignored (37% in Shah's patients) [12]. Ferlito and al. searched the literature to try to determine the best neck dissection strategy in patients with cN0 laryngeal SCC. Analysis of data from seven

prospective, multicentric studies showed respectively that only 1.4% (4 out of 272 patients) and 3.4% (6 out of 175) had occult nodal metastasis in level IIb and IV (6 out of 175). The overall rate of metastasis (all levels) was estimated at 26%. The authors concluded that selective neck dissection in levels IIa and III should be enough in cN0 patients [11]. In 2007, Paleri and al. conducted a prospective study to estimate the rate of occult metastasis in level IIb in SCC of the upper airways and digestive tract in cN0 patients [13]. Only one out of 230 patients (0.4%) had positive nodes in level IIb. These data seem similar to our results. Indeed, level II and III were the most frequently affected, with a prevalence of 11.5 % (9 patients). On the contrary, the incidences of cervical metastasis at level IIb and IV was respectively 1.3 % (1 patient) and 1.3 % (1 patient).

In the literature, no significant correlation was detected between the risk of occult nodal metastasis and tumor sublocalization and tumor stage, probably because of a lack of statistical power. However, in our study, despite of the non-statistically significant difference between the rate of occult metastases and tumor stage, all patients who showed occult nodal metastasis in histological analysis had locally advanced T3 or T4 tumors. It seems logical insofar these advanced laryngeal cancers are supposed very lymphophilic (either supraglottic, subglottic or transglottic) [14].

The development of organ preservation strategies radically changed the management of patients with SCC of the larynx. With the exception of patients with laryngeal carcinoma invading cartilages (T4a), most of total laryngectomies today are carried out in a salvage situation following the failure of non-surgical treatment [15, 16]. In the literature, the rate of occult metastasis following a TL for recurrence following local radiotherapy of the larynx and lymph nodes is extremely variable (0-20 %) [17, 18, 19, 20, 21].

Concerning the place of elective neck dissection in salvage TL following radiotherapy, some studies seem to show that a strategy of sparing lymph nodes does not alter overall survival

and recurrence free survival but reduces both operating time and the incidence of postoperative complications, in particular the risk of pharyngocutaneous fistula [20, 22, 23].

In 2010, Bohannon and al. conducted a retrospective study comparing 71 cN0 patients who had undergone salvage TL after radiotherapy: lymph nodes were dissected in one group and spared in the other [20]. No significant difference was demonstrated between the two groups about global survival ($p=0.47$) or recurrence free survival ($p=0.5$). In contrast, there were significantly more postoperative complications after neck dissection ($p=0.04$). The authors concluded that lymph node dissection did not prolong survival in these patients but other experts still recommend elective neck dissection in the case of locally advanced recurrent tumors even though no impact on survival has been demonstrated in the relevant studies [17, 18, 19, 24].

To minimize postoperative morbidity after systematic elective neck dissection in a patient with cN0 neck, two strategies can be considered:

- In patients free of any radiotherapy, elective neck dissection seems to be necessary. Indeed, in our series, 14 % of patients had an occult nodal metastasis. This should be highly selective and could be confined to levels IIa and III in regards of the low risk of metastasis in these areas. The omission of level IV neck dissection seems justified but the literature is poor on this level so these data must be confirmed by other studies. Cervical lymph node dissection would allow an accurate nodal staging, a surgical treatment of the lymph nodes and an optimization of the radiotherapy fields.

- in patients treated by a salvage TL after the failure of radiotherapy or chemoradiotherapy including the cervical lymph nodes, elective neck dissection seems to increase the risk of postoperative complications as well as the duration of the operation, without enhancing survival. Moreover, some studies have reported a very low incidence of occult nodal metastasis following preoperative radiotherapy of the lymph node regions. These results are similar to our series. Thus, elective neck dissection does not seem to be justified.

However, a complementary, prospective, multicentric study will be required to confirm our results.

Conclusion

The rate of occult nodal metastasis in levels IIb and IV in patients with cN0 laryngeal SCC requiring TL is very low. It seems justified to omit the dissection of level IIB in elective treatment in accordance with many other studies. The omission of Level IV neck dissection is an interesting perspective, less studied and which need to be confirmed in multicentric studies on a larger population. In addition, preoperative radiotherapy of lymph node-containing areas may protect against nodal dissemination. It is therefore legitimate to question about the benefit of neck lymph node dissection in these patients. Indeed, this procedure is associated with a significant morbidity.

References :

- [1] Barroso Ribeiro R, Ribeiro Breda E, Fernandes Monteiro E. Prognostic significance of nodal metastasis in advanced tumors of the larynx and hypopharynx. *Acta Otorrinolaringol Esp.* 2012; 63:292-298.
- [2] Mamelle G, Pampurik J, Luboinski B, et al. Lymph node prognostic factors in head and neck squamous cell carcinomas. *Am J Surg.* 1994;168(5):494-8.
- [3] Moe K, Wolf GT, Fisher SG, et al. Regional metastasis in patients with advanced laryngeal cancer. *Arch Otolaryngol Head Neck Surg.* 1996;122:644-8.
- [4] Ferlito A, Silver CE, Suárez C, et al. Preliminary multi-institutional prospective pathologic and molecular studies support preservation of sublevel IIB and level IV for laryngeal squamous carcinoma with clinically negative neck. *Eur Arch Otorhinolaryngol.* 2007; 264:111-114; discussion 109.
- [5] Paydarfar JA, Birkmeyer NJ. Complications in head and neck surgery: a meta-analysis of postlaryngectomy pharyngocutaneous fistula. *Arch Otolaryngol Head Neck Surg.* 2006; 132:67-72.
- [6] Celik B, Coskun H, Kumas FF et al. Accessory nerve function after level 2b-preserving selective neck dissection. *Head Neck.* 2009;31:1496-501.
- [7] Santoro R, Franchi A, Gallo O et al. Nodal metastases at level IIb during neck dissection for head and neck cancer: clinical and pathologic evaluation. *Head Neck.* 2008;30:1483-7.

[8] Villaret AB, Piazza C, Peretti G et al. Multicentric prospective study on the prevalence of sublevel IIB metastases in head and neck cancer. *Arch Otolaryngol Head Neck Surg.* 2007;133:897-903.

[9] Robbins KT, Clayman G, Levine PA et al. Neck dissection classification update: revisions proposed by the American Head and Neck Society and the American Academy of Otolaryngology-Head and Neck Surgery. *Arch Otolaryngol Head Neck Surg.* 2002; 128:751-758.

[10] Pfister DG, Spencer S, Brizel DM et al. Head and neck cancers, Version 2.2014. Clinical practice guidelines in oncology. *J Natl Compr Canc Netw.* 2014; 12:1454-1487.

[11] Ferlito A, Silver CE, Rinaldo A. Selective neck dissection (IIA, III): a rational replacement for complete functional neck dissection in patients with N0 supraglottic and glottic squamous carcinoma. *Laryngoscope.* 2008; 118:676-679.

[12] Shah JP. Patterns of cervical lymph node metastasis from squamous carcinomas of the upper aerodigestive tract. *Am J Surg.* 1990; 160:405-409.

[13] Paleri V, Kumar Subramaniam S, Oozeer N, et al. Dissection of the submuscular recess (sublevel IIB) in squamous cell cancer of the upper aerodigestive tract: prospective study and systematic review of the literature. *Head Neck.* 2008; 30:194-200.

[14] Mutlu V, Ucuncu H, Altas E, et al. The Relationship between the Localization, Size, Stage and Histopathology of the Primary Laryngeal Tumor with Neck Metastasis. *Eurasian J Med.* 2014 Feb; 46(1): 1–7.

- [15] Weber RS, Berkey BA, Forastiere A, et al. Outcome of salvage total laryngectomy following organ preservation therapy: the Radiation Therapy Oncology Group trial 91-11. *Arch Otolaryngol Head Neck Surg.* 2003; 129:44-49.
- [16] Forastiere AA, Goepfert H, Maor M, et al. Concurrent chemotherapy and radiotherapy for organ preservation in advanced laryngeal cancer. *N Engl J Med.* 2003; 349:2091-2098.
- [17] Amit M, Hilly O, Leider-Trejo L, et al. The role of elective neck dissection in patients undergoing salvage laryngectomy. *Head Neck.* 2013; 35:1392-1396.
- [18] Wax MK, Touma BJ. Management of the N0 neck during salvage laryngectomy. *Laryngoscope.* 1999; 109:4-7.
- [19] Yao M, Roebuck JC, Holsinger FC, et al. Elective neck dissection during salvage laryngectomy. *Am J Otolaryngol.* 2005; 26:388-392.
- [20] Bohannon IA, Desmond RA, Clemons L, et al. Management of the N0 neck in recurrent laryngeal squamous cell carcinoma. *Laryngoscope* 2010; 120:58-61.
- [21] Farrag TY, Lin FR, Cummings CW et al. Neck management in patients undergoing postradiotherapy salvage laryngeal surgery for recurrent/persistent laryngeal cancer. *Laryngoscope.* 2006; 116:1864-1866.
- [22] Andrades P, Pehler SF, Baranano CF, et al. Fistula analysis after radial forearm free flap reconstruction of hypopharyngeal defects. *Laryngoscope.* 2008; 118:1157-1163.

[23] Withrow KP, Rosenthal EL, Gourin CG et al. Free tissue transfer to manage salvage laryngectomy defects after organ preservation failure. *Laryngoscope*. 2007; 117:781-784.

[24] Johnson JT. Carcinoma of the larynx: selective approach to the management of cervical lymphatics. *Ear Nose Throat J*. 1994; 73:303-305.

Table 1. Characteristics of the Study Population	n (%)
Number of patients	78 (100%)
Sex	
Male	72 (92%)
Female	6 (8%)
Tumor stage	
cT2N0	4 (5%)
cT3N0	30 (39%)
cT4aN0	44 (56%)
Sub-site	
Glottic	25 (32%)
Subglottic	3 (4%)
Supraglottic	7 (9%)
Transglottic	43 (55%)
Type of surgery	
Primary TL	37 (47%)
Salvage TL	41 (53%)

TL : Total Laryngectomy

Table 2. Characteristics of patients showing occult nodal metastases

Case	Age (years)	Sex	Recurrence	Initial treatment: radiotherapy	Initial treatment: other	pTN stage	Site of the primary tumor	Neck dissection		Level of positive lymph nodes	Follow-up time (months)
								side	level		
1	60	F	yes	no	laser cordectomy	rT4aN2b	glotto-subglottic	bilat	II-IV, VIb	IIa (I)	29
2	50	M	no	-	-	T3N1	supraglottic	ipsilat	II-IV	IIa (I)	31
3	54	M	no	-	-	T4aN1	transglottic	bilat	II-IV	III (I)	33
4	83	F	yes	no	laser cordectomy	rT4aN1	subglottic	bilat	II-IV	III (I)	53
5	71	M	no	-	-	T4aN1	transglottic	bilat	II-IV	IIb (I)	40
6	64	M	no	-	-	T3N1	transglottic	bilat	II-IV	IIa (I)	4
7	61	M	no	-	-	T4aN1	transglottic	ipsilat	II-IV	IIa (I)	85
8	59	M	no	-	-	T4aN1	transglottic	bilat	II-IV, VI	IIa (I)	33
9	65	M	yes	no	failure of induction CT	yT3N2b	supraglottic	ipsilat	II-IV	IIa (I)	89
10	72	M	no	-	-	T4aN2b	transglottic	ipsilat	II-IV	IV (I)	5
11	79	M	no	-	-	T4aN2c	glotto-subglottic	bilat	II-IV	IIa (C)	47

M: male, F: female, CT: chemotherapy, I: ipsilateral, C: contralateral

List of titles:

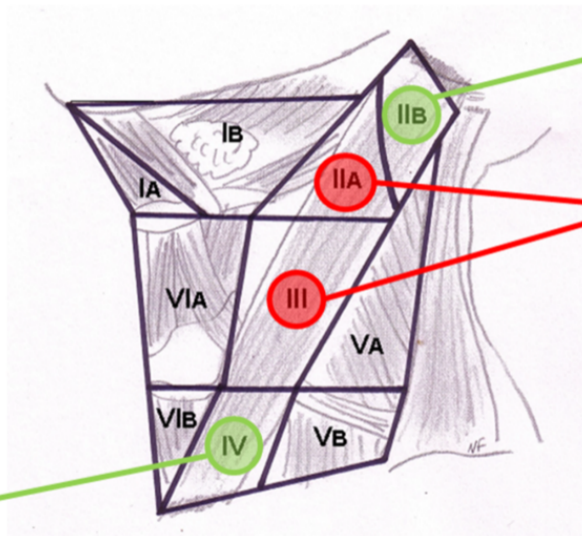
Table 1: Characteristics of the Study Population

Table 2: Characteristics of patients showing occult nodal metastases

Figure 1: Distribution of occult nodal metastases by level

Conflict of interest : None

N=1 (1,3%)



N=1 (1,3%)

N=9 (11,5%)