



**HAL**  
open science

## Progression of adenomyosis magnetic resonance imaging features under ulipristal acetate for symptomatic fibroids

Lisa Calderon, Antoine Netter, Anaïs Grob-Vaillant, Julien Mancini, Pascale Siles, Vincent Vidal, Aubert Agostini

### ► To cite this version:

Lisa Calderon, Antoine Netter, Anaïs Grob-Vaillant, Julien Mancini, Pascale Siles, et al.. Progression of adenomyosis magnetic resonance imaging features under ulipristal acetate for symptomatic fibroids. *Reproductive BioMedicine Online*, Elsevier, 2021, 42 (3), pp.661-668. 10.1016/j.rbmo.2020.11.012 . hal-03216026

**HAL Id: hal-03216026**

**<https://hal-amu.archives-ouvertes.fr/hal-03216026>**

Submitted on 13 Jan 2022

**HAL** is a multi-disciplinary open access archive for the deposit and dissemination of scientific research documents, whether they are published or not. The documents may come from teaching and research institutions in France or abroad, or from public or private research centers.

L'archive ouverte pluridisciplinaire **HAL**, est destinée au dépôt et à la diffusion de documents scientifiques de niveau recherche, publiés ou non, émanant des établissements d'enseignement et de recherche français ou étrangers, des laboratoires publics ou privés.

# Progression of adenomyosis magnetic resonance imaging features under ulipristal acetate for symptomatic fibroids



## BIOGRAPHY

Dr Antoine Netter is currently pursuing a fellowship in advanced gynaecologic surgery at Aix-Marseille University in France. His research mainly focuses on endometriosis and human reproduction.

Lisa Calderon<sup>1</sup>, Antoine Netter<sup>2,3,\*</sup>, Anaïs Grob-Vaillant<sup>1</sup>, Julien Mancini<sup>4</sup>, Pascale Siles<sup>5</sup>, Vincent Vidal<sup>1</sup>, Aubert Agostini<sup>2</sup>

## KEY MESSAGE

The MRI features of adenomyosis seem to progress under a 3-month treatment course of daily 5 mg doses of ulipristal acetate (UPA). These findings do not encourage further research on the use of UPA as a treatment for adenomyosis.

## ABSTRACT

**Research question:** What is the evolution of adenomyosis on magnetic resonance imaging (MRI) after a 3-month treatment course of daily 5 mg doses of ulipristal acetate (UPA) for symptomatic fibroids?

**Design:** A monocentric prospective pilot study on patients who underwent a 3-month treatment course of UPA for symptomatic fibroids between January 2014 and December 2017. Patients underwent pelvic MRI shortly before (pre-MRI) and after treatment (post-MRI). The diagnosis of adenomyosis on MRI was defined by the observation of intramyometrial cysts and/or haemorrhagic foci within these cystic cavities and/or a thickening of the junctional zone  $>12$  mm. The progression of adenomyosis was defined by the presence of at least one of the aforementioned criteria of adenomyosis on the pre-MRI and by at least one of the following on the post-MRI: (i) increased thickness of the junctional zone  $\geq 20\%$  and/or (ii) increased number of intramyometrial cysts. The appearance of adenomyosis was defined by the absence of the aforementioned criteria of adenomyosis on the pre-MRI and the presence of at least one of these criteria on the post-MRI.

**Results:** Seventy-two patients were included. The MRI features of adenomyosis progressed for 12 of 15 patients (80.0%) for whom adenomyosis was identified on the pre-MRI. An appearance of adenomyosis was identified after treatment for 15 of 57 patients (26.3%) for whom adenomyosis was not identified on the pre-MRI.

**Conclusions:** A 3-month treatment course of daily 5 mg doses of UPA could provoke a short-term progression or an emergence of typical adenomyosis intramyometrial cysts on MRI examinations.

<sup>1</sup> Department of Medical Imaging, Assistance Publique Hôpitaux de Marseille, La Timone Hospital, Aix Marseille University, Marseille 13005, France

<sup>2</sup> Department of Obstetrics and Gynecology, Assistance Publique Hôpitaux de Marseille, La Conception Hospital, Aix Marseille University, Marseille 13005, France

<sup>3</sup> Institut Méditerranéen de Biodiversité et d'Écologie marine et continentale (IMBE), Aix Marseille University, CNRS, IRD, Avignon University, Marseille, France

<sup>4</sup> Aix Marseille University, APHM, INSERM, IRD, SESSTIM, Public Health Department, La Timone Hospital, BIOTIC, 264 Rue Saint Pierre, 13005 Marseille 05, Marseille, France

<sup>5</sup> Department of Women's Health Imaging, Assistance Publique Hôpitaux de Marseille, La Timone Hospital, Aix Marseille University, Marseille 13005, France

## KEYWORDS

Adenomyosis  
Magnetic resonance imaging  
MRI  
Ulipristal acetate

## INTRODUCTION

Ulipristal acetate (UPA) has been approved for use in Europe for the treatment of symptomatic fibroids since 2012 (Donnez *et al.*, 2018). This drug has been proven to be efficient for reducing uterine bleeding and correcting anaemia prior to fibroid surgery (Donnez *et al.*, 2012a, 2012b, 2014, 2015). Approximately 765,000 patients had received this treatment between February 2012 and May 2018 when the European Medicines Agency issued new measures to restrict its use after reports of several cases of hepatic failure (Donnez *et al.*, 2018; European Medicines Agency, 2018).

Selective progesterone receptor modulators (SPRM) such as UPA are used for their mixed progesterone agonist–antagonist properties on the myometrium and the endometrium in various contexts (i.e. contraception, abortion, uterine fibroids and endometriosis) (Chabbert-Buffet *et al.*, 2005). However, also because of these properties, there is particular vigilance of the endometrial changes that UPA could potentially induce (Donnez *et al.*, 2012a). Non-physiological histological endometrial changes are commonly observed immediately after a 3-month treatment course of UPA (Donnez *et al.*, 2012a). Progesterone receptor modulator-associated endometrial changes (PAEC) are characterized by epithelial architectural distortion, by cystically dilated glands and, in one-third of cases, by extensive cyst formation (Williams *et al.*, 2012). These histological modifications, although benign and spontaneously reversible, have never been observed elsewhere, therefore suggesting a very specific effect of SPRM on the endometrium.

Adenomyosis is a uterine disorder defined by the presence of endometrial tissue within the myometrium (Vannuccini *et al.*, 2017). The pathogenesis of adenomyosis has not been fully elucidated but the most likely theory would involve the invasion of the myometrium by the endometrium through a down-growth and an invagination (García-Solares *et al.*, 2018; Vannuccini *et al.*, 2017). This process appears to be mediated by numerous pathogenic pathways, including a down-regulation of progesterone receptors inducing progesterone resistance (Nie

*et al.*, 2010). Adenomyosis and uterine fibroids share similarities in terms of their symptomatology, (e.g. uterine bleeding, infertility and pain). For reasons that are not fully understood, both uterine pathologies are often concomitant (41–57%) (Bazot and Daraï, 2018; Brucker *et al.*, 2014; Filip *et al.*, 2019). Thus, given the widespread use of UPA in recent years, it is reasonable to assume that this treatment has been received by a large number of women who presented with adenomyosis. Despite this supposed exposure of adenomyotic women to UPA and its known influence on progesterone receptors that are also involved in the pathogenesis of adenomyosis, only two studies have investigated the effect of UPA on adenomyosis. Conway *et al.* (2019) reported cases of six patients with adenomyosis erroneously treated by UPA. Their results, although limited by the small sample size, suggest that UPA worsens the symptoms and ultrasound features of adenomyosis. Gracia *et al.* (2018) conducted a retrospective analysis of 41 patients who were treated with UPA for uterine fibroids and who also presented with adenomyosis. They concluded that the UPA treatment led to a significant reduction of the symptoms of adenomyosis but did not report the evolution of the ultrasound features of adenomyosis. In addition, Olivier and Jacques Donnez recently reported the case of a 36-year-old woman with adenomyosis who was treated with UPA for 3 months. Both her symptoms and the MRI features of adenomyosis were aggravated by the treatment (Donnez and Donnez, 2020). Thus, further studies are needed to determine the impact of UPA treatment on women presenting with adenomyosis.

This study sought to determine the effect of a 3-month treatment course of daily 5 mg doses of UPA on the evolution of the MRI features of adenomyosis in patients treated prior to surgery for uterine fibroids.

## MATERIALS AND METHODS

### Study design

This was a prospective pilot study conducted between January 2014 and December 2017 in the Department of Medical Imaging at La Timone Hospital, Marseille, France. The study was approved by an independent ethics committee on 8 February 2015 (CEROG 2014-GYN-1103).

### Study population

The study population partly overlaps with the one described in a previous paper reporting the variation in the volume of fibroids subsequent to UPA treatment (Netter *et al.*, 2019). All premenopausal patients who presented for consultation for symptomatic uterine fibroids received detailed information about the study and the UPA treatment. Women willing to undergo delayed surgery after a 3-month treatment course of daily 5 mg doses of UPA were considered for inclusion and were requested to provide written consent. Patients were eligible for inclusion if they had uterine bleeding and/or abdominal pain and/or other symptoms that could be attributed to uterine fibroids. The exclusion criteria were contraindications to magnetic resonance imaging (MRI) (e.g. ferromagnetic implants, claustrophobia), contraindications to UPA treatment (e.g. pregnancy, previously known hypersensitivity), interruption of treatment within 3 months or fibroid surgery before the end of the 3 months, previous fibroid treatment with either gonadotrophin-releasing hormone (GnRH) agonists or UPA, previous fibroid or uterine surgeries, and an inability to provide written consent.

### MRI assessment of adenomyosis

Patients underwent pelvic MRI shortly before (pre-MRI) and after (post-MRI) treatment (not more than 1 month before and after treatment) at the Women's Health Imaging Department at La Timone Hospital in Marseille, France. MRI were performed with an MRI Siemens Spectra 3.0T device (Siemens AG, Munich, Germany). The MRI protocol was T2-weighted sagittal and axial ( $\pm$  coronal) sequences and axial T1- and T1FS-weighted sequences. Sagittal T2-weighted sequences were acquired with a field of view of 250 mm and 4 mm sections with a 1.4 mm intersection gap using a 320  $\times$  320 matrix.

Every MRI was independently interpreted after the end of the study period by two experienced radiologists (LC and AG-V) who did not know whether the MRI had been performed before or after treatment. In cases of disagreement about the presence of adenomyosis, the MRI at issue could be re-examined jointly by the two radiologists to reach consensus.

The diagnosis of adenomyosis on MRI was defined by the observation of at

least one of the following features: (i) intramyometrial cysts represented by cystic cavities (small high signal intensity foci on T2-weighted sequences) and/or haemorrhagic foci within these cystic cavities (small high signal intensity foci on T1-weighted sequences) and/or (ii) a thickening of the junctional zone >12 mm (Bazot et al., 2001; Dueholm et al., 2001; Reinhold et al., 1996). The junctional zone was identified on T2-weighted sequences as the distinct inner lower signal area that separates the central endometrium (high signal intensity) from the outer myometrium (intermediate signal) (Brown et al., 1991; Scoutt et al., 1991). The maximal thickness of the junctional zone was defined by the greatest antero-posterior dimension measured on sagittal T2-weighted sequences and only in areas without fibroids. When the junctional zone could not be accurately measured and if no intramyometrial cyst was identified, then the diagnosis of adenomyosis was not retained.

The progression of adenomyosis after the UPA treatment was defined by the presence at least one of the aforementioned criteria of adenomyosis on the pre-MRI and by at least one of the following on the post-MRI: (i) increased thickness of the junctional zone  $\geq 20\%$  and/or (ii) increased number of intramyometrial cysts. The appearance of adenomyosis was defined by the absence of the aforementioned criteria of adenomyosis on the pre-MRI and the presence of at least one of these criteria on the post-MRI.

The pre- and post-MRI were classified by subtypes based on the localization of adenomyosis according to the classification suggested by Kishi et al. (2012), which was enhanced by Bazot and Daraï (2018): (i) intrinsic or internal adenomyosis (focal or diffuse) when adenomyosis was limited to the inner layer of the uterus in direct connection to the junctional zone without affecting the outer structures; (ii) extrinsic or external adenomyosis when limited to the outer shell of the uterus without connection to the junctional zone; (iii) intramural adenomyosis when occurring alone unrelated to the junctional zone or the serosa; and (iv) indeterminate when adenomyosis did not meet the criteria for any of the aforementioned subtypes or when adenomyosis was only diagnosed by an isolated thickening of the junctional

zone >12 mm (Bazot and Daraï, 2018; Kishi et al., 2012).

Through a secondary unblinded interpretation by both radiologists, the aspect of the endometrium was compared between the pre- and post-MRI. PAEC was suspected when the endometrium was thicker after the treatment and presented new cystic dilatations (Williams et al., 2012). The suspicion of PAEC was retained only when both radiologists agreed on the presence of these aforementioned criteria.

#### End-points

The primary end-points were the percentage of patients for whom adenomyosis progressed among the patients presenting adenomyosis on the pre-MRI and the percentage of patients for whom adenomyosis appeared after UPA treatment among patients who did not present adenomyosis on the pre-MRI. The secondary end-point was the percentage of patients for whom a PAEC was suspected on the post-MRI among patients who presented a progression or an appearance of adenomyosis.

#### Statistical analysis

Due to the absence of prior data regarding the evolution of adenomyosis under UPA treatment, no sample size could be estimated for this pilot study. All patients who were treated with UPA during the study period and who met the selection criteria were included.

The baseline characteristics of the patients are reported as the mean  $\pm$  SD or the median (minimum–maximum) for quantitative variables and as counts (percentages) for categorical variables.

Categorical variables were compared using Fisher's exact test. Variations before and after the MRI were compared using McNemar's test for qualitative variables and the paired Wilcoxon test for quantitative variables. The comparison of suspicion of PAEC between progressive adenomyosis and non-progressive adenomyosis was performed using Pearson's chi-squared test.

All statistical analyses were two-tailed, and results were considered significant when  $P$ -values <0.05 were obtained. These analyses were performed using SPSS Statistics for Windows, Version 20.0 (IBM Corp., Armonk, NY, USA).

## RESULTS

### Population

Between January 2014 and December 2017, 73 patients were considered for inclusion. After the exclusion of one patient who underwent surgery before the end of the UPA treatment, 72 patients were included in the final analysis. The mean age was  $39.4 \pm 5.8$  years. The median gravidity and parity were 2 (0–8) and 1 (0–7), respectively.

### Interobserver agreement

Among the 72 patients included, the radiologists disagreed about the presence of adenomyosis only for three patients (4.2%). The radiologists disagreed about the presence of adenomyosis on the pre-MRI for one patient. The presence of adenomyosis was ruled out for this patient after a secondary analysis by both radiologists. Adenomyosis was also absent on the post-MRI for this patient. The radiologists disagreed about the appearance of adenomyosis on the post-MRI for two patients. The presence of adenomyosis was confirmed for these two patients after a secondary analysis.

The agreement between observers regarding the count of intramyometrial cysts and the measurement of the junctional zone was excellent (Cohen's kappa = 0.947 and 0.838, respectively;  $P < 0.001$  for both).

### Evolution of adenomyosis under UPA

Among the 72 patients included, 15 were diagnosed with adenomyosis on the pre-MRI (TABLE 1).

Twelve of these 15 patients (80.0%) had an increased number of intramyometrial cysts after the UPA treatment than before. The median number of intramyometrial cysts was significantly greater after treatment (10 [2–30]) than before (2 [0–10];  $P = 0.002$ ). In three patients, who only presented a thickening of the junctional zone >12 mm without intramyometrial cysts on the pre-MRI, intramyometrial cysts were observed on the post-MRI (FIGURE 1).

The median thickness of the junctional zone was similar before (13.5 [2–21] mm) and after the UPA treatment (11.0 [5–21] mm;  $n = 14$ ;  $P = 0.640$ ). Only three patients had an increased thickness of the junctional zone  $\geq 20\%$ , all of whom also had an increased number of intramyometrial cysts.

**TABLE 1 MRI CHARACTERISTICS OF PATIENTS FOR WHOM ADENOMYOSIS WAS DIAGNOSED ON THE MRI BEFORE THE UPA TREATMENT (N = 15)**

	n	MRI before UPA treatment	MRI after UPA treatment	P-value <sup>a</sup>
Diagnosis of adenomyosis				
Junctional zone >12 mm	15	8/15 (53)	6/15 (40)	–
type="Other" Presence of intramyometrial cysts	15	12/15 (80)	15/15 (100)	–
Classification of adenomyosis				
Focal internal adenomyosis	15	10/15 (67)	10/15 (67)	–
Diffuse internal adenomyosis	15	1/15 (7)	4/15 (27)	–
Intramural adenomyoma	15	1/15 (7)	1/15 (7)	–
External adenomyosis	15	0/15 (0)	0/15 (0)	–
Isolated thickening of the junctional zone	15	3/15 (20)	0/15 (0)	–
Number of intramyometrial cysts, median (minimum–maximum)	15	2 (0–10)	10 (2–30)	0.002**
Thickness of the junctional zone (mm), median (minimum–maximum)	14	13.5 (2–21)	11.0 (5–21)	0.640
Progression of adenomyosis				
Increased thickness of the junctional zone ≥20%	14	–	3/14 (21)	–
Increased number of intramyometrial cysts	15	–	12/15 (80)	–
PAEC	15	–	9/15 (60)	–

Data are presented as n (%).

\*\* P-value ≤0.01.

MRI = magnetic resonance imaging; PAEC = progesterone receptor modulator-associated endometrial changes; UPA = ulipristal acetate.

<sup>a</sup> Only the statistical analyses to compare the number of intramyometrial cysts and the thickness of the junctional zone before and after the treatment were conducted.

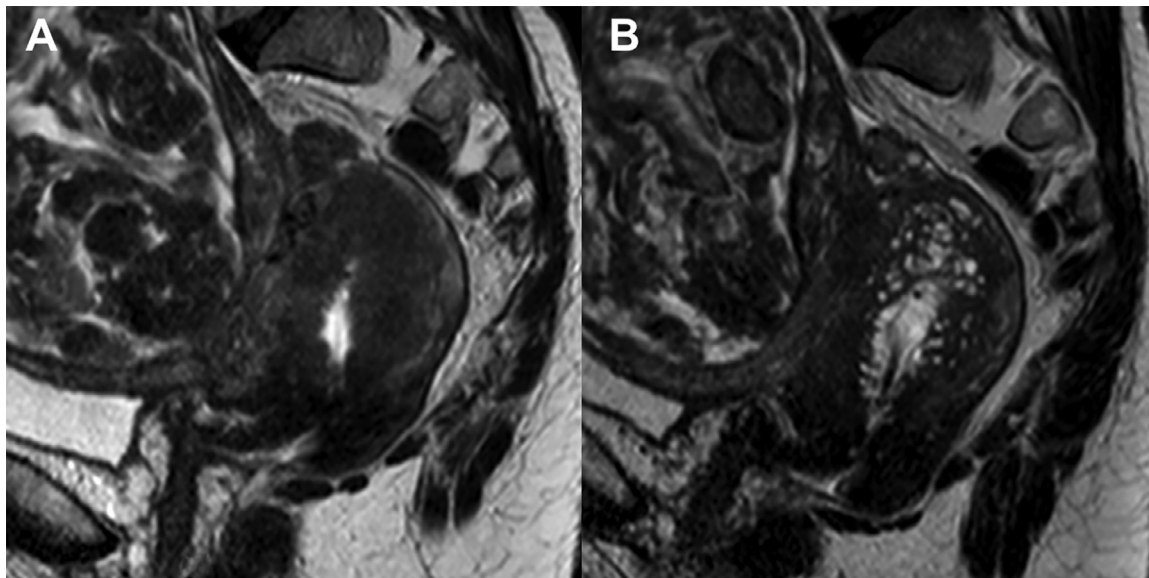
### Appearance of adenomyosis under UPA

Adenomyosis was not observed on the pre-MRI for 57 of the 72 patients included (TABLE 2). Among these 57 patients, the appearance of adenomyosis was observed on the post-MRI for 15 patients (26.3%). The appearance of adenomyosis after treatment was

exclusively represented by emerging intramyometrial cysts (FIGURE 2). The median number of intramyometrial cysts among these patients on the MRI after treatment was 3 (2–20). The median thickness of the junctional zone was the same before (7.0 [3–11] mm; n = 12) and after treatment (7.5 [3–13] mm; n = 13; P = 0.670).

### Classification of adenomyosis

Eleven of the 15 patients (73.3%) who were diagnosed with adenomyosis on the pre-MRI had internal adenomyosis (TABLE 1). These 11 patients still had internal adenomyosis on the post-MRI; for nine of these patients, the intramyometrial cysts increased in number after treatment. One patient



**FIGURE 1** Example of a progression of adenomyosis after ulipristal acetate (UPA) treatment on T2-weighted sagittal sequences. (A) Magnetic resonance imaging (MRI) before UPA treatment; (B) MRI after UPA treatment.

**TABLE 2 MRI CHARACTERISTICS OF PATIENTS FOR WHOM ADENOMYOSIS APPEARED AFTER THE UPA TREATMENT (N = 15)**

	n	MRI before UPA treatment	n	MRI after UPA treatment	P-value
Diagnosis of adenomyosis					
Junctional zone >12 mm	-	-	15	2/15 (13)	-
Presence of intramyometrial cysts	-	-	15	15/15 (100)	-
Classification of adenomyosis					
Focal internal adenomyosis	-	-	15	14/15 (93)	-
Diffuse internal adenomyosis	-	-	15	0/15 (0)	-
Intramural adenomyoma	-	-	15	0/15 (0)	-
External adenomyosis	-	-	15	1/15 (7)	-
Isolated thickening of the junctional zone	-	-	15	0/15 (0)	-
Number of intramyometrial cysts, median (minimum–maximum)	-	-	15	3 (2–20)	-
Thickness of the junctional zone (mm), median (minimum–maximum)	12	7.0 (3–11)	13	7.5 (3–13)	0.670
PAEC	-	-	15	5/15 (33)	

Data are presented as n (%).

MRI = magnetic resonance imaging; PAEC = progesterone receptor modulator-associated endometrial changes; UPA = ulipristal acetate.

<sup>a</sup>Only the statistical analyses to compare the number of intramyometrial cysts and the thickness of the junctional zone before and after the treatment were conducted.

was diagnosed with an intramural adenomyoma, which remained unchanged on the post-MRI. Three patients were diagnosed with an isolated thickening of the junctional zone >12 mm without any direct criteria. Internal adenomyosis appeared on the post-MRI for all three of these patients.

Fourteen of the 15 patients (93%) for whom adenomyosis appeared on the post-MRI had internal diffuse adenomyosis (TABLE 2). For one patient, who was not diagnosed with adenomyosis

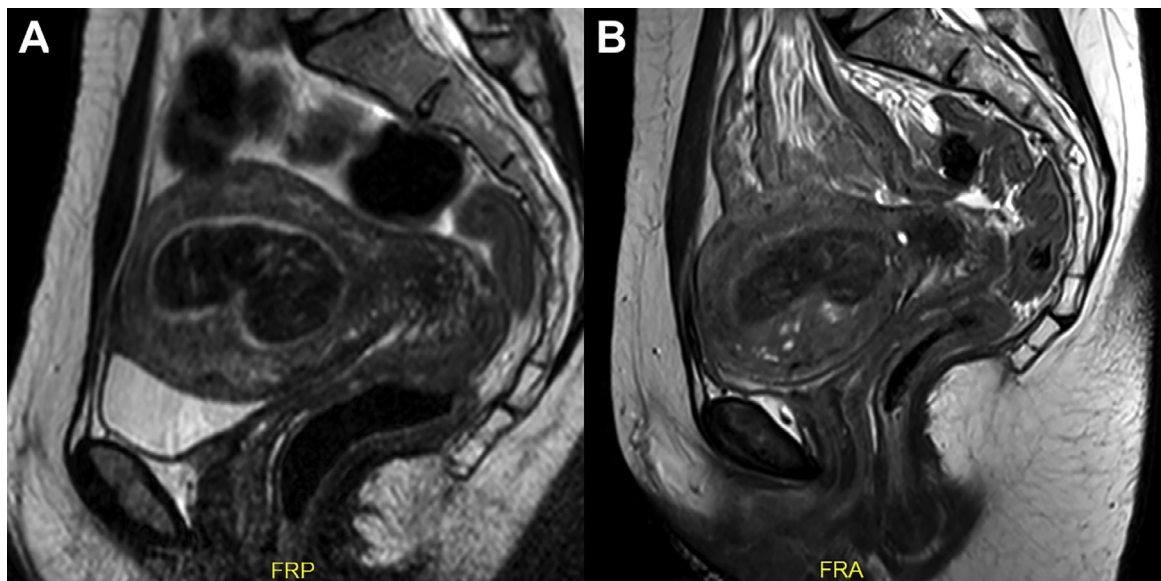
on the pre-MRI, external adenomyosis was observed on the post-MRI.

#### Association with the suspicion of PAEC

PAEC were suspected on the post-MRI in 24 of the 72 patients included (33%). Among the 30 patients who either had a progression or an appearance of adenomyosis, 14 (46.7%) presented a suspicion of PAEC on the MRI after UPA treatment. Among the 42 patients who presented neither a progression nor an appearance of adenomyosis, PAEC was suspected for 10 (23.8%;  $P = 0.042$ ).

## DISCUSSION

This is the largest study to report the evolution of adenomyosis in response to a 3-month treatment course of 5 mg daily doses of UPA on prospectively collected MRI. The results suggest that UPA induces either a short-term progression or an appearance of typical intramyometrial adenomyotic cysts in a large proportion of the patients treated. A progression was assessed in 12/15 (80%) of patients who already had adenomyosis, and an appearance



**FIGURE 2** Example of an appearance of adenomyosis after ulipristal acetate (UPA) treatment on T2-weighted sagittal sequences. (A) Magnetic resonance imaging (MRI) before UPA treatment; (B) MRI after UPA treatment.

occurred for 15/57 (26%) of patients who did not have adenomyosis before the treatment. Although the intramyometrial cysts seem to increase in number, the junctional zone does not seem to be impacted by the UPA treatment. PAEC were more frequently suspected in patients for whom adenomyosis either progressed or appeared. As these MRI modifications are involved in distinct layers of the uterus, they are unlikely to be confused with one another. However, it was not possible to verify the presence of PAEC with histological data for this study and therefore the strength of the association between PAEC and the emergence or progression of adenomyosis cannot be accurately reported. Nevertheless, this concomitant emergence of endometrial (PAEC) and myometrial (intramyometrial cysts) observations on MRI suggest that UPA treatment exerts the same effect on both eutopic and ectopic endometrium. According to this hypothesis, the progression of MRI features of adenomyosis under UPA treatment observed in this study would only be an illustration of PAEC occurring in the intramyometrial endometrium.

Only two other studies have investigated the effect of UPA on adenomyosis. *Gracia et al. (2018)* retrospectively compared 41 patients who underwent a 3-month treatment course of 5 mg daily doses of UPA for symptomatic fibroids and who also presented ultrasound features of adenomyosis to 122 patients who only had uterine fibroids without adenomyosis. They concluded that UPA treatment was even more effective for treating pelvic pain and uterine bleeding in patients who presented with adenomyosis and uterine fibroids than in patients who only presented with uterine fibroids. They did not report any data on the evolution of adenomyosis features on ultrasound. The retrospective nature of this study and the statistical arrangements of data are major impediments to interpretation of their results. *Conway et al. (2019)* reported a case series of six patients who erroneously received a 3-month treatment course of 5 mg daily doses of UPA for adenomyosis. All six patients presented worsened symptoms of adenomyosis (dysmenorrhoea, pelvic pain, dyspareunia and bowel symptoms) after the treatment than before. However, these symptoms were retrospectively assessed, as recalled by

the patients, which impairs the reliability of the results. The sonographic features were reportedly enhanced after the UPA treatment in comparison with the ultrasounds before the treatment, which were not performed in their unit. More recently, Olivier and Jacques Donnez reported the case of a patient presenting with adenomyosis who received a 3-month treatment course of UPA (*Donnez and Donnez, 2020*). The symptoms worsened during the treatment and MRI features of adenomyosis were aggravated at the end of treatment with an increased number of intramyometrial cysts. One year after the end of the UPA treatment, an MRI showed further worsening of adenomyosis with an increased uterine volume and a severe full-thickness adenomyosis. The patient's quality of life was also greatly impaired. The worsening of adenomyosis MRI features due to UPA treatment described in this report is very similar to what was observed in the current study.

In comparison, the prospective design, standardized treatment course and MRI protocol carried out for this study ensured a more reliable assessment of the evolution of adenomyosis under UPA. Although ultrasound is an effective and inexpensive means of diagnosis of adenomyosis, MRI remains more convenient for such studies because it allows images of the same patient to be compared at different times and the reproducibility of the technique can be increased by limiting the number of radiologists involved and by assessing the inter- and/or intraobserver reliability. Both direct (intramyometrial cysts) and indirect (thickness of the junctional zone) criteria were used to assess the presence of adenomyosis on MRI. Both criteria share the same impediment, namely the lack of sensitivity (*Bazot and Darai, 2018*). Studies comparing imaging and histological outcomes have reported that intramyometrial cysts are only observed in half of the MRI when adenomyosis is assessed histologically (*Bazot et al., 2001; Reinhold et al., 1996*). As stated by *Bazot and Darai (2018)*, measurement of the junctional zone is perilous, particularly with the presence of uterine fibroids, and should therefore not be used as a sole criterion to diagnose adenomyosis. Indeed, in the current study, the junctional zone was not measurable in 29% of MRI. Using the two criteria instead of only one criterion

increases sensitivity with a minimal loss of specificity because intramyometrial cysts are pathognomonic and a junctional zone >12 mm is fairly specific for adenomyosis (*Bazot and Darai, 2018; Champaneria et al., 2010*). However, interpretation of the results must be measured by a few considerations. Firstly, this study only provides imaging information, and whether any patients presented symptoms of adenomyosis before treatment or how these symptoms evolved after treatment cannot be stated. The most common symptoms of adenomyosis are uterine bleeding and pelvic pain (*Chapron et al., 2020*). Although the PEARL studies clearly demonstrated that UPA was effective in reducing these symptoms in the context of uterine fibroids, the particular population of women affected by both uterine fibroids and adenomyosis was not investigated (*Donnez et al., 2012a, 2012b*). Thus, the clinical evolution of these patients remains unresolved. The myometrial MRI changes described in this study should not be overly interpreted as a sign of aggravation of adenomyosis on their own, and clinical evaluation remains paramount. Secondly, MRI were conducted immediately after the UPA treatment for this study and it is therefore impossible to determine whether the emerging intramyometrial cysts would spontaneously regress as has been described for PAEC (*Donnez et al., 2012a, 2012b*). The evaluation of the long-term evolution would have required a third MRI months after the end of the UPA treatment, which was not conceivable for this study given that the vast majority of the patients underwent surgery shortly after the end of treatment. Thirdly, adenomyosis was not histologically confirmed and although intramyometrial cysts are fairly specific of adenomyosis, other intramyometrial changes specific to UPA cannot be ruled out, especially because the thickness of the junctional zone remained unchanged after treatment. Finally, this being a pilot study on a limited number of patients that could not be calculated beforehand, and given the paucity of the scientific literature on this specific matter, generalization of the conclusions remains uncertain.

The pathogenesis of adenomyosis, while still debated, involves sex steroid hormone aberrations with an increase of oestrogen receptor activity and a down-regulation of progesterone receptors

(Kitawaki et al., 2000; Nie et al., 2010; Oehler et al., 2004; Vannuccini et al., 2017). These hormonal modifications have been described as the primary elements of a cascade of reactions involving numerous molecular pathways and resulting in the invasion of the myometrium by endometrial tissue (Vannuccini et al., 2017). The association between selective oestrogen receptor modulators (SERM) such as tamoxifen, which is prescribed for breast cancers in postmenopausal women, and the presence of adenomyosis has long been described (Cohen et al., 1998; McCluggage et al., 2000). Similar data are missing for SPRM. In 2017, an observational study with histological and molecular analyses of endometrial samples to determine the effect of UPA on the endometrium was conducted (Whitaker et al., 2017). The UPA treatment altered the expression of mRNA encoding sex steroid receptors. Progesterone receptors were expressed in differential manners within the endometrium, with a down-regulation within the stroma and an up-regulation within the glandular epithelium. These altered gene expressions could somehow explain the emergence or the progression of adenomyosis that were observed in the present study.

Thus, the results of this study suggest that a 3-month treatment course of daily 5 mg doses of UPA could provoke a short-term progression or an emergence of typical adenomyosis intramyometrial cysts on MRI exams. Although no clinical data about the evolution of symptoms is reported, these results do not encourage further research on the use of UPA as a treatment for adenomyosis.

## REFERENCES

- Bazot, M., Cortez, A., Darai, E., Rouger, J., Chopier, J., Antoine, J.M., Uzan, S. **Ultrasonography compared with magnetic resonance imaging for the diagnosis of adenomyosis: correlation with histopathology.** Hum. Reprod. 2001; 16: 2427–2433. doi:10.1093/humrep/16.11.2427
- Bazot, M., Darai, E. **Role of transvaginal sonography and magnetic resonance imaging in the diagnosis of uterine adenomyosis.** Fertil. Steril. 2018; 109: 389–397. doi:10.1016/j.fertnstert.2018.01.024
- Brown, H.K., Stoll, B.S., Nicosia, S.V., Fiorica, J.V., Hambley, P.S., Clarke, L.P., Silbiger, M.L. **Uterine junctional zone: correlation between histologic findings and MR imaging.** Radiology 1991; 179: 409–413. doi:10.1148/radiology.179.2.1707545
- Brucker, S.Y., Huebner, M., Wallwiener, M., Stewart, E.A., Ebersoll, S., Schoenfisch, B., Taran, F.A. **Clinical characteristics indicating adenomyosis coexisting with leiomyomas: a retrospective, questionnaire-based study.** Fertil. Steril. 2014; 101. doi:10.1016/j.fertnstert.2013.09.038
- Chabbert-Buffet, N., Meduri, G., Bouchard, P., Spitz, I.M. **Selective progesterone receptor modulators and progesterone antagonists: mechanisms of action and clinical applications.** Hum. Reprod. Update 2005; 11: 293–307. doi:10.1093/humupd/dmi002
- Champaneria, R., Abedin, P., Daniels, J., Balogun, M., Khan, K.S. **Ultrasound scan and magnetic resonance imaging for the diagnosis of adenomyosis: systematic review comparing test accuracy.** Acta Obstet. Gynecol. Scand. 2010; 89: 1374–1384. doi:10.3109/00016349.2010.512061
- Chapron, C., Vannuccini, S., Santulli, P., Abrão, M.S., Carmona, F., Fraser, I.S., Gordts, S., Guo, S.-W., Just, P.-A., Noël, J.-C., Pistofidis, G., Van den Bosch, T., Petraglia, F. **Diagnosing adenomyosis: an integrated clinical and imaging approach.** Hum. Reprod. Update 2020. doi:10.1093/humupd/dmz049
- Cohen, I., Shapira, J., Beyth, Y., Bernheim, J., Tepper, R., Cordoba, M., Altaras, M.M. **Estrogen and progesterone receptors of adenomyosis in postmenopausal breast cancer patients treated with tamoxifen.** Gynecol. Obstet. Invest. 1998; 45: 126–131. doi:10.1159/000009939
- Conway, F., Morosetti, G., Camilli, S., Martire, F.G., Sorrenti, G., Piccione, E., Zupi, E., Exacoustos, C. **Ulipristal acetate therapy increases ultrasound features of adenomyosis: a good treatment given in an erroneous diagnosis of uterine fibroids.** Gynecol. Endocrinol. 2019; 35: 207–210. doi:10.1080/09513590.2018.1505846
- Donnez, J., Arriagada, P., Marciniak, M., Larrey, D. **Liver safety parameters of ulipristal acetate for the treatment of uterine fibroids: a comprehensive review of the clinical development program.** Expert Opin. Drug Saf. 2018; 17: 1225–1232. doi:10.1080/14740338.2018.1550070
- Donnez, J., Hudecek, R., Donnez, O., Matule, D., Arhndt, H.-J., Zatik, J., Kasilovskiene, Z., Dumitrascu, M.C., Fernandez, H., Barlow, D.H., Bouchard, P., Fauser, B.C.J.M., Bestel, E., Terrill, P., Osterloh, I., Loumaye, E. **Efficacy and safety of repeated use of ulipristal acetate in uterine fibroids.** Fertility and Sterility 2015; 103. doi:10.1016/j.fertnstert.2014.10.038
- Donnez, J., Tatarchuk, T.F., Bouchard, P., Puscasiu, L., Zakharenko, N.F., Ivanova, T., Ugocsai, G., Mara, M., Jilla, M.P., Bestel, E., Terrill, P., Osterloh, I., Loumaye, E. **Ulipristal Acetate versus Placebo for Fibroid Treatment before Surgery.** New England Journal of Medicine 2012; 366: 409–420. doi:10.1056/NEJMoa1103182
- Donnez, J., Tomaszewski, J., Vázquez, F., Bouchard, P., Lemieszczuk, B., Baró, F., Nouri, K., Selvaggi, L., Sodowski, K., Bestel, E., Terrill, P., Osterloh, I., Loumaye, E. **Ulipristal Acetate versus Leuprolide Acetate for Uterine Fibroids.** New England Journal of Medicine 2012; 366: 421–432. doi:10.1056/NEJMoa1103180
- Donnez, J., Vázquez, F., Tomaszewski, J., Nouri, K., Bouchard, P., Fauser, B.C.J.M., Barlow, D.H., Palacios, S., Donnez, O., Bestel, E., Osterloh, I., Loumaye, E. **Long-term treatment of uterine fibroids with ulipristal acetate.** Fertility and Sterility 2014; 101. doi:10.1016/j.fertnstert.2014.02.008
- Donnez, O., Donnez, J. **Gonadotropin-releasing hormone antagonist (linzagolix): a new therapy for uterine adenomyosis.** Fertility and Sterility 2020. doi:10.1016/j.fertnstert.2020.04.017
- Dueholm, M., Lundorf, E., Hansen, E.S., Sørensen, J.S., Ledertoug, S., Olesen, F. **Magnetic resonance imaging and transvaginal ultrasonography for the diagnosis of adenomyosis.** Fertil. Steril. 2001; 76: 588–594. doi:10.1016/s0015-0282(01)01962-8
- European Medicines Agency. **Esmya: new measures to minimise risk of rare but serious liver injury [WWW Document].** European Medicines Agency 2018 <https://www.ema.europa.eu/en/medicines/human/referrals/esmya>
- Filip, G., Balzano, A., Cagnacci, A. **Histological evaluation of the prevalence of adenomyosis, myomas and of their concomitance.** Minerva Ginecol. 2019; 71: 177–181. doi:10.23736/S0026-4784.18.04291-0
- García-Solares, J., Donnez, J., Donnez, O., Dolmans, M.-M. **Pathogenesis of uterine adenomyosis: invagination or metaplasia?** Fertil. Steril. 2018; 109: 371–379. doi:10.1016/j.fertnstert.2017.12.030
- Gracia, M., Alcalá, M., Ferreri, J., Rius, M., Ros, C., Saco, M.A., Martínez-Zamora, M.Á., Carmona, F. **Ulipristal Acetate Improves Clinical Symptoms in Women with Adenomyosis and Uterine Myomas.** J. Minim. Invasive Gynecol. 2018; 25: 1274–1280. doi:10.1016/j.jmig.2018.04.002
- Kishi, Y., Suginami, H., Kuramori, R., Yabuta, M., Suginami, R., Taniguchi, F. **Four subtypes of adenomyosis assessed by magnetic resonance imaging and their specification.** Am. J. Obstet. Gynecol. 2012; 207. doi:10.1016/j.ajog.2012.06.027
- Kitawaki, J., Koshihara, H., Ishihara, H., Kusuki, I., Tsukamoto, K., Horjo, H. **Progesterone induction of 17beta-hydroxysteroid dehydrogenase type 2 during the secretory phase occurs in the endometrium of estrogen-dependent benign diseases but not in normal endometrium.** J. Clin. Endocrinol. Metab. 2000; 85: 3292–3296. doi:10.1210/jcem.85.9.6829
- McCluggage, W.G., Desai, V., Manek, S. **Tamoxifen-associated postmenopausal**



- adenomyosis exhibits stromal fibrosis, glandular dilatation and epithelial metaplasias.** *Histopathology* 2000; 37: 340–346. doi:10.1046/j.1365-2559.2000.01001.x
- Netter, A., Pauly, V., Siles, P., Pivano, A., Vidal, V., Agostini, A. **Predictors of uterine fibroid volume reduction under ulipristal acetate: a prospective MRI study.** *Reprod. Biomed. Online* 2019; 39: 795–801. doi:10.1016/j.rbmo.2019.07.028
- Nie, J., Liu, X., Guo, S.-W. **Promoter hypermethylation of progesterone receptor isoform B (PR-B) in adenomyosis and its rectification by a histone deacetylase inhibitor and a demethylation agent.** *Reprod. Sci.* 2010; 17: 995–1005. doi:10.1177/1933719110377118
- Oehler, M.K., Greschik, H., Fischer, D.-C., Tong, X., Schuele, R., Kieback, D.G. **Functional characterization of somatic point mutations of the human estrogen receptor alpha (hERalpha) in adenomyosis uteri.** *Mol. Hum. Reprod.* 2004; 10: 853–860. doi:10.1093/molehr/gah113
- Reinhold, C., McCarthy, S., Bret, P.M., Mehio, A., Atri, M., Zakarian, R., Glaude, Y., Liang, L., Seymour, R.J. **Diffuse adenomyosis: comparison of endovaginal US and MR imaging with histopathologic correlation.** *Radiology* 1996; 199: 151–158. doi:10.1148/radiology.199.1.8633139
- Scoutt, L.M., Flynn, S.D., Luthringer, D.J., McCauley, T.R., McCarthy, S.M. **Junctional zone of the uterus: correlation of MR imaging and histologic examination of hysterectomy specimens.** *Radiology* 1991; 179: 403–407. doi:10.1148/radiology.179.2.2014282
- Vannuccini, S., Tosti, C., Carmona, F., Huang, S.J., Chapron, C., Guo, S.-W., Petraglia, F. **Pathogenesis of adenomyosis: an update on molecular mechanisms.** *Reprod. Biomed. Online* 2017; 35: 592–601. doi:10.1016/j.rbmo.2017.06.016
- Whitaker, L.H.R., Murray, A.A., Matthews, R., Shaw, G., Williams, A.R.W., Saunders, P.T.K., Critchley, H.O.D. **Selective progesterone receptor modulator (SPRM) ulipristal acetate (UPA) and its effects on the human endometrium.** *Hum. Reprod.* 2017; 32: 531–543. doi:10.1093/humrep/dew359
- Williams, A.R.W., Bergeron, C., Barlow, D.H., Ferenczy, A. **Endometrial morphology after treatment of uterine fibroids with the selective progesterone receptor modulator, ulipristal acetate.** *Int. J. Gynecol. Pathol.* 2012; 31: 556–569. doi:10.1097/PGP.0b013e318251035b